LATISSIMUS DORSI

OVERVIEW

The latissimus dorsi is a broad, flat muscle covering the mid-back. It is named for its size and location. It has 3 compartments and twists nearly 180 degrees around the teres major. The distal end of latissimus dorsi is often in the same compartment as teres major.

It is usually innervated in six separate sections by the thoracodorsal nerve. It originates along the axial skeleton and attaches to the humerus, making it an extrinsic back muscle.

ATTACHMENTS

Latissimus dorsi attaches to most bones of the axial skeleton below T6, except for a few ribs. Via the thoracolumbar fascia, it originates along the iliac crest, sacrum, lumbars and the last 7 Thoracic vertebrae. The muscle fibers stop far short of the iliac crest and lumbars but extend closer to the thoracics.

The superior border attaches to the inferior border of the scapula directly or by a slip of connective tissue about 75% of the time.

It twists around the teres major and often shares the same compartment as it passes along the axilla. It inserts along the medial lip and floor of the bicipital groove in a tendon that us usually fused with the fibers of teres major.

FUNCTION

The latissimus dorsi depresses the humerus and shoulder girdle. This can make naming its functions complex, depending on the humerus' starting position. When in front of the body, as when chopping wood, it extends the humerus. When the humerus is behind the body, as when dipping on bars, latissimus dorsi flexes the humerus. When the arm is abducted laterally, as when dribbling a basketball out to the side, it is adducting the arm.

The lateral compartment is more involved and developed by movement that pull the down when high overhead or out to the side. The transverse compartment is more involved in movements that pull the humerus and shoulder girdle posteriorly, as when rowing.

WHEN ORIGIN IS FIXED

- Depression of shoulder girdle
- Adduction of shoulder girdle
- Adduction of humerus
- Extension of humerus

Medial rotation of humerus

WHEN INSERTION IS FIXED

- Tilt pelvis anterior
- Tilt pelvis laterally
- Hyperextension of spine

NEUROMUSCULAR CONSIDERATIONS

The latissimus dorsi os often overlooked in postural distortion and addressed too late in the treatment plan. It is easy to adjust posture so that the lats are slack and not generating pain, except in brief moments of stretch or contraction. The C-shaped side-bend that is indicative of unilateral shortness is often attributed to other muscles that are contracted to keep the lat from being painfully stretched. When bilaterally short, the chest caves and the diaphragm closes. These muscles that are short to bend the torso and protect the lat(s) often become the focus of structural corrections.

The trigger points along the floating ribs do not often generate enough pain for the client to complain but create strong restrictions in the low back. The quadratus lumborum and erectors cn be very difficult to release without first releasing these governing trigger points.

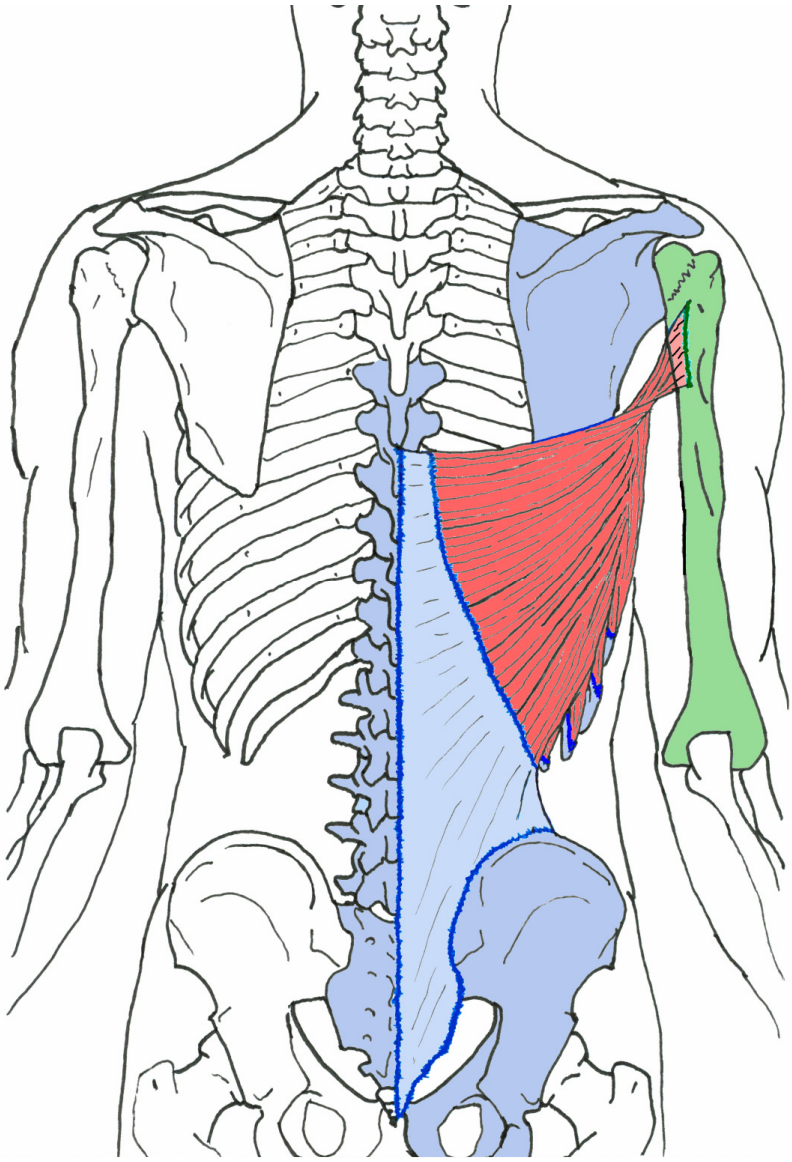

- LATISSIMUS DORSI

Origin

- T6-L5, sacrum and iliac crest via the thoracolumbar fascia
- The last 3-4 ribs
- Often attaches to the inferior angle of the scapula

Insertion

- Floor of the bicipital groove via a tendon that partially fuses with the teres major tendon.

Function

- Extension of the humerus
- Medial rotation of the humerus
- Adduction of the humerus

